

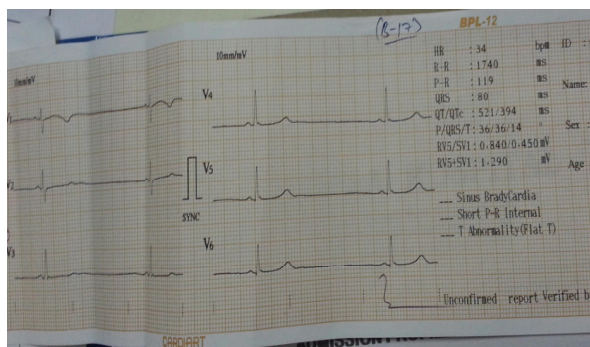
## Alarming bradycardia in a patient with Dengue fever

**Dear Editor:**

As we notice a spurt in the number of patients getting admitted to the intensive care units with Dengue fever following monsoon so also is the varied presentation of the clinical symptoms of this intriguing disease [1]. One such benign presentation is relative bradycardia which is well known with Dengue fever [2].

We often come across patients with asymptomatic bradycardia and don't pay much heed as it resolves spontaneously over a period of days to weeks. There are various explanations for its pathogenesis which may result commonly from viral myocarditis [3] and immune mediated dysfunction of the Sino a trial node.

**Fig-1:** ECG from our patient showing Sinus Bradycardia



A 26-year-old female patient was admitted to our hospital with fever and joint pains. On routine clinical testing she was found to have thrombocytopenia. Serology of Dengue confirmed the diagnosis. Subsequently patient developed extreme bradycardia with a heart rate of only thirty-four beats per minute.

Although our patient was haemodynamically stable an extreme degree of bradycardia raised an alarm among the treating doctors and immediate decision had to be taken whether to treat this immediately or wait as the patient was asymptomatic. A twelve lead ECG confirmed

Sinus bradycardia. Other causes of bradycardia like Hypothyroidism, Electrolyte imbalance and structural heart disease were ruled out. Patient was admitted to a high dependency unit and observed. A cardiology consultation was taken and patient was started on Tab.Orciprenaline per oral 10 milligrams eighth hourly. In spite of this patient showed a very slow improvement in the heart rate and the maximum heart rate noticed was around 44 beats per minute.

Over a period of two days' patient recovered spontaneously with improvement in platelet count and was discharged without any further rhythm disturbances. Patient was followed up after a week and had normal heart rate. We would like to bring this to the notice of readers that even though bradycardia is documented with Dengue fever this severity has not been reported in the literature to our knowledge so far. One study [4] noted the lowest heart rate to be around 42 per minute.

Various infections cause relative bradycardia and in the differential diagnosis one should always keep in mind the important causes for the same. The common causes are Dengue, Typhoid, Leptospirosis, Psittacosis, Babesiosis and Legionnaires disease. Though Dengue being quite common any fever presenting with relative bradycardia treating doctors should rule this DD first.

Pathophysiology varies and some studies have shown the direct virus mediated Myocarditis as the possible cause. Other studies have addressed the role of immune mediated dysfunction of the SA node in causing relative bradycardia in these infections. A possible role of Cytokines is also suggested by some authors but requires further studies to confirm their role.

In conclusion Dengue fever is a known cause of relative bradycardia and often patients recover spontaneously without any specific treatment. A combination of bradycardia and Dengue Shock

Syndrome can be catastrophic and the treating physician must be well aware of such complications.

### References

1. Nimmagadda SS, Mahabala C, Bolor A, Raghuram PM, Nayak UA. Atypical manifestations of Dengue Fever (DF) - Where do we stand today? *J ClinDiagn Res.* 2014; 8(1):71-73.
2. Lim SMS, Hoo FK, Sulaiman WAW. A case of dengue hemorrhagic fever with myocarditis and complete heart block. *RMJ.* 2014; 39(1):104-106.
3. Martha JW. Total atrioventricular block due to Dengue myocarditis. *J Cardiovasc Electrophysiol.* 2009; 20(S59):1045-3873.
4. Sharda M, Gupt A, Nagar D, Soni AK. Dengue Fever: An Additional Cause for Bradycardia. *J Assoc Physicians India.* 2014; 62(4):362-3.

**I.A. Khan<sup>1</sup>, Altaf Ahmed<sup>1</sup>, Sha Ruknuddin<sup>1</sup> and Zahid Ahmed<sup>\*2</sup>**

<sup>1</sup>Department of Medicine and <sup>2</sup>Department of Anesthesia and Intensive Care, Shifaa Hospital, No-332, Darussalam, Queens Road, Bangalore-560052, Karnataka, India

---

\*All correspondences to: Dr. Zahid Ahamed, Department of Anesthesia and Intensive Care, Shifaa Hospital, No-332, Darussalam, Queens Road, Bangalore-560052, Karnataka, India. E-mail: zahid99.a@gmail.com